

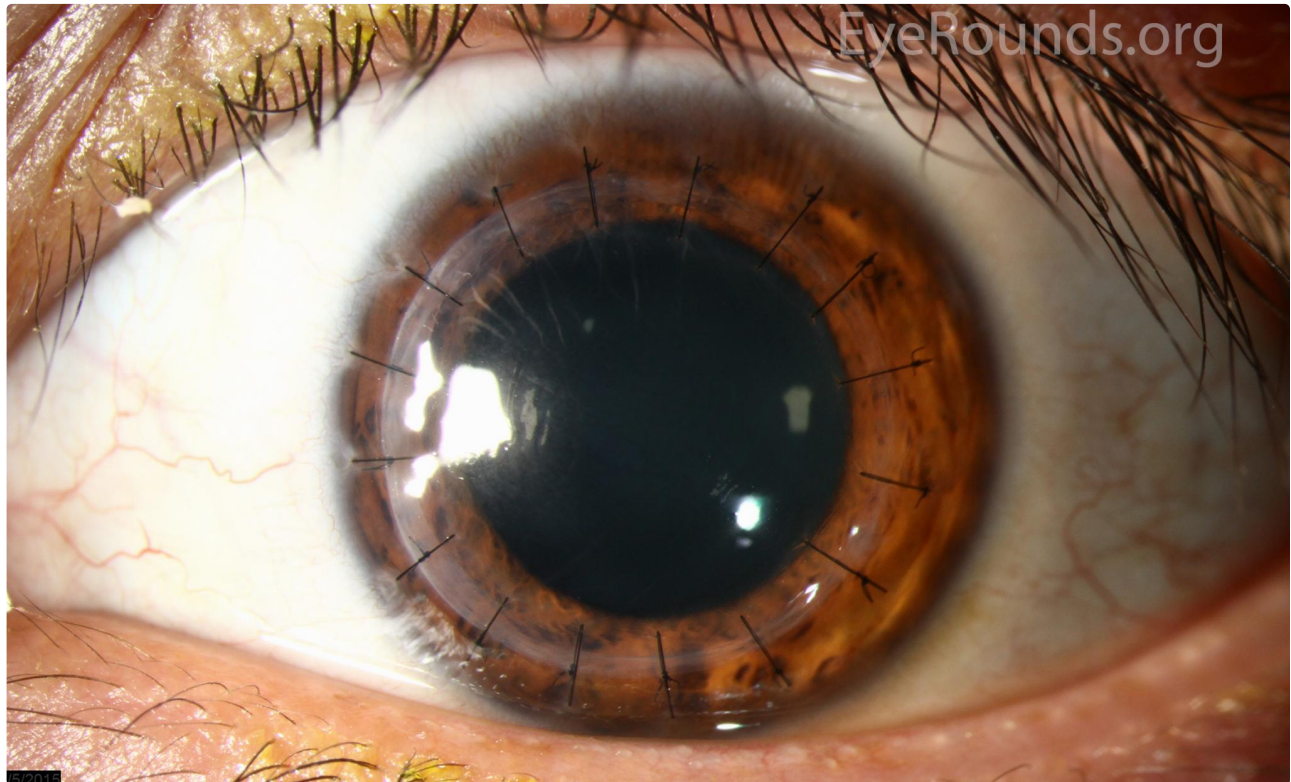
Penetrating keratoplasty (PK)

Category(ies): Cornea

Contributor: [Jesse Vislisel, MD](#)

Photographer: Antoinette Venckus, CRA (A), Stefani Karakas, CRA (B, C, E, F), and Brice Critser, CRA (D)

These images show the post-operative appearance of 4 different patients after penetrating keratoplasty (PK), or full-thickness corneal transplantation. PK grafts may be secured using interrupted sutures (A, B), running sutures (C), or a combination of both (D). Sutures are usually removed during the post-operative period. Grafts may remain clear for decades with proper care, as seen in this patient 30 years after the procedure with all sutures removed (E, F). [Read the related article](#) for more information regarding modern corneal transplantation techniques.

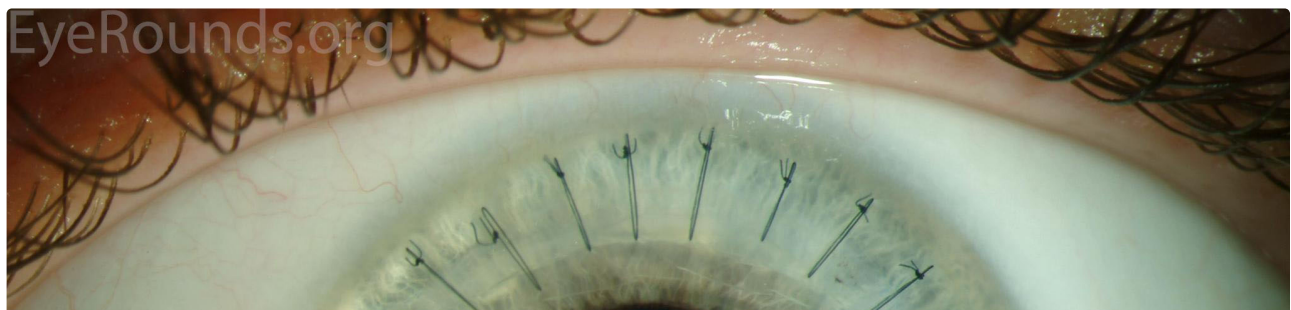

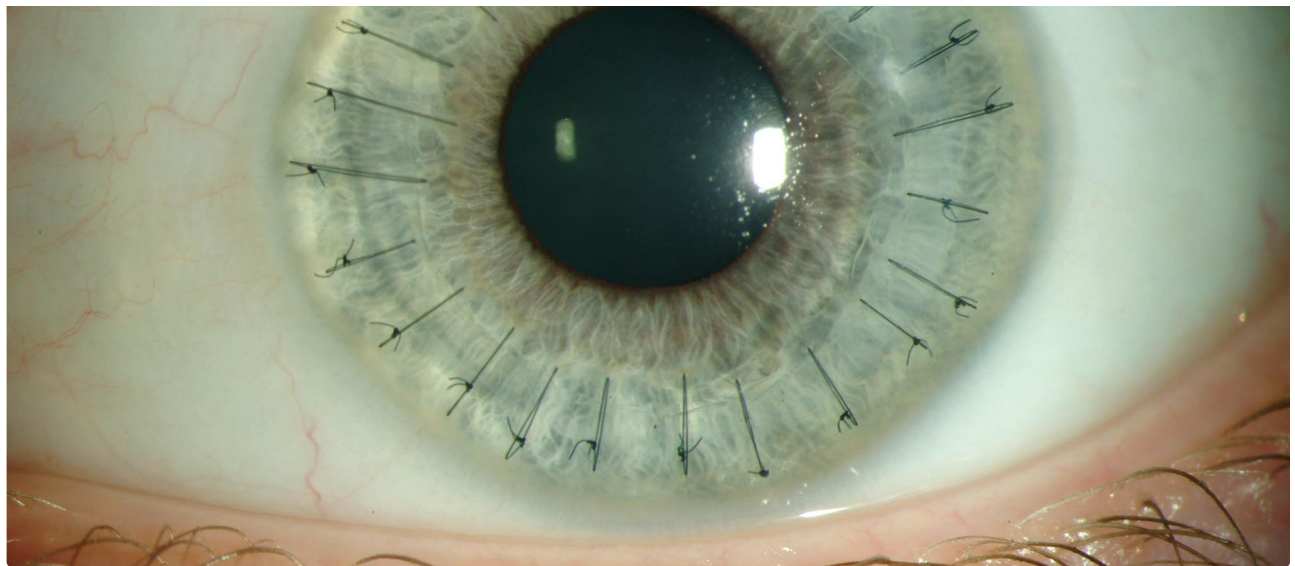
5/2016

Interrupted sutures

Enlarge

Download

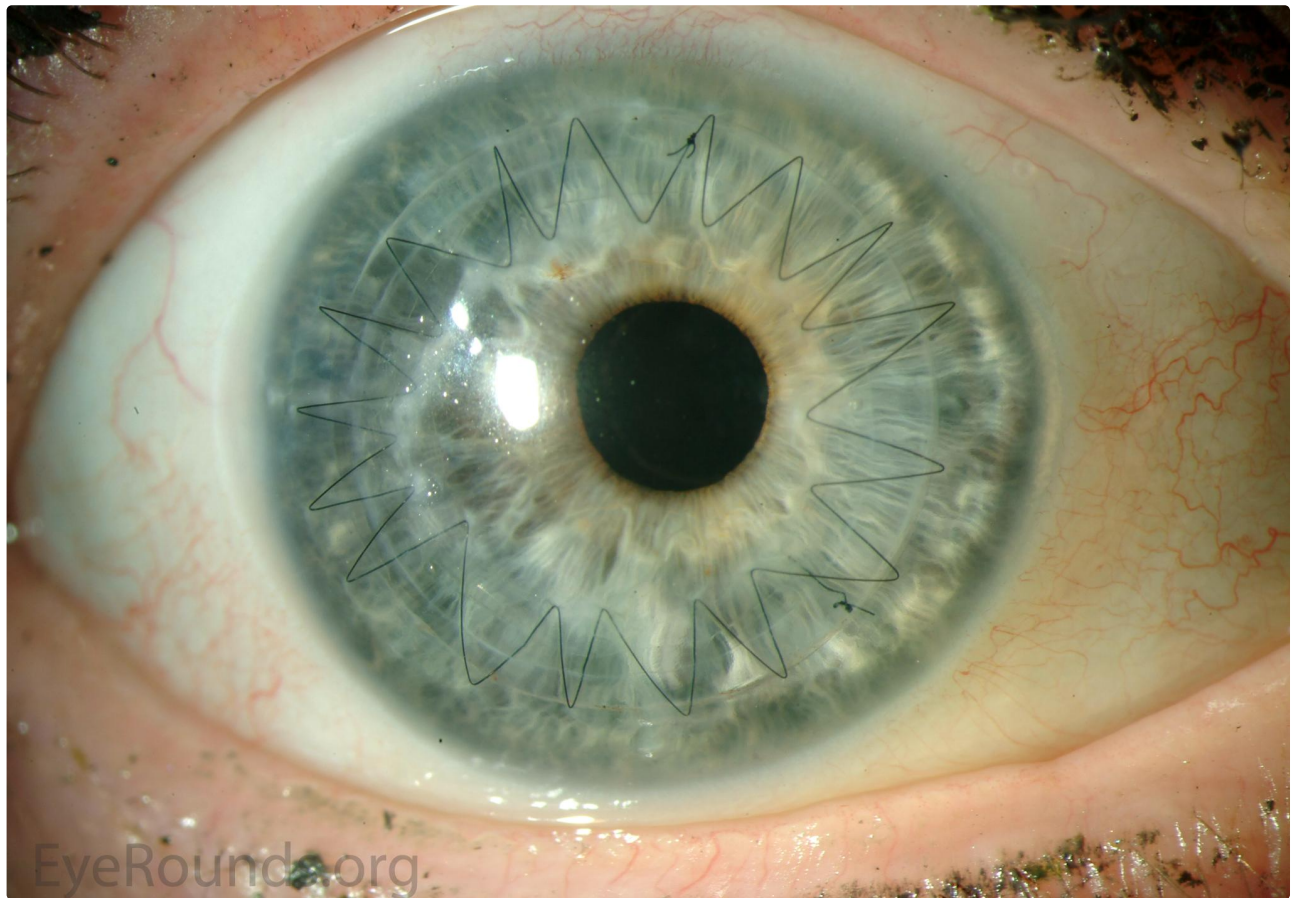




Interrupted sutures

[Enlarge](#)

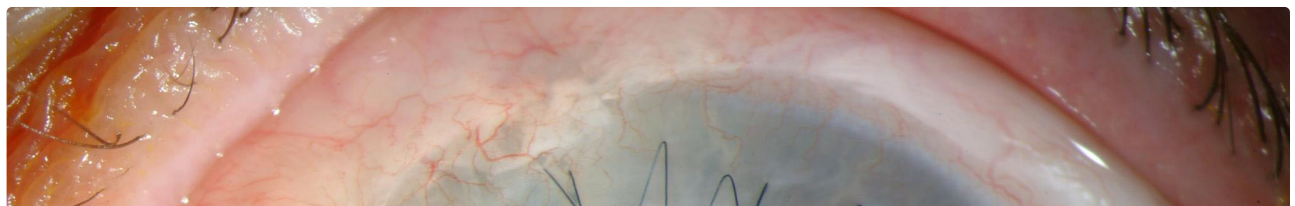
[Download](#)

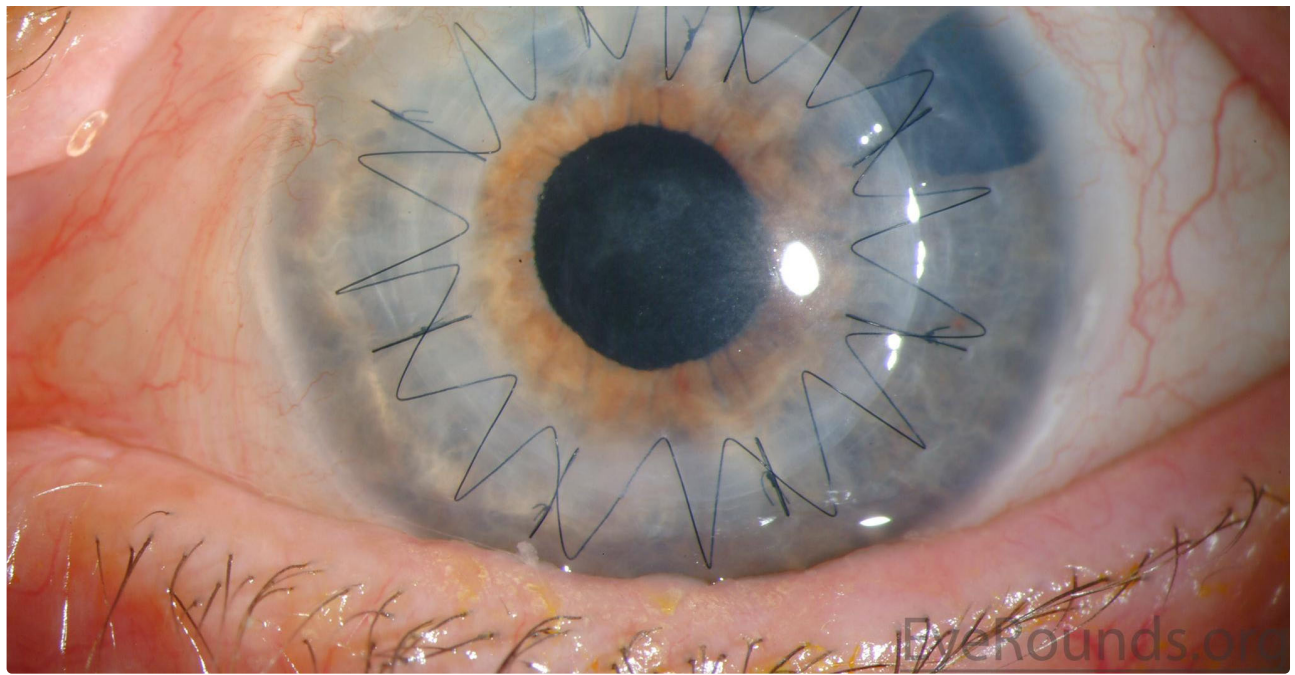


Running Sutures

[Enlarge](#)

[Download](#)

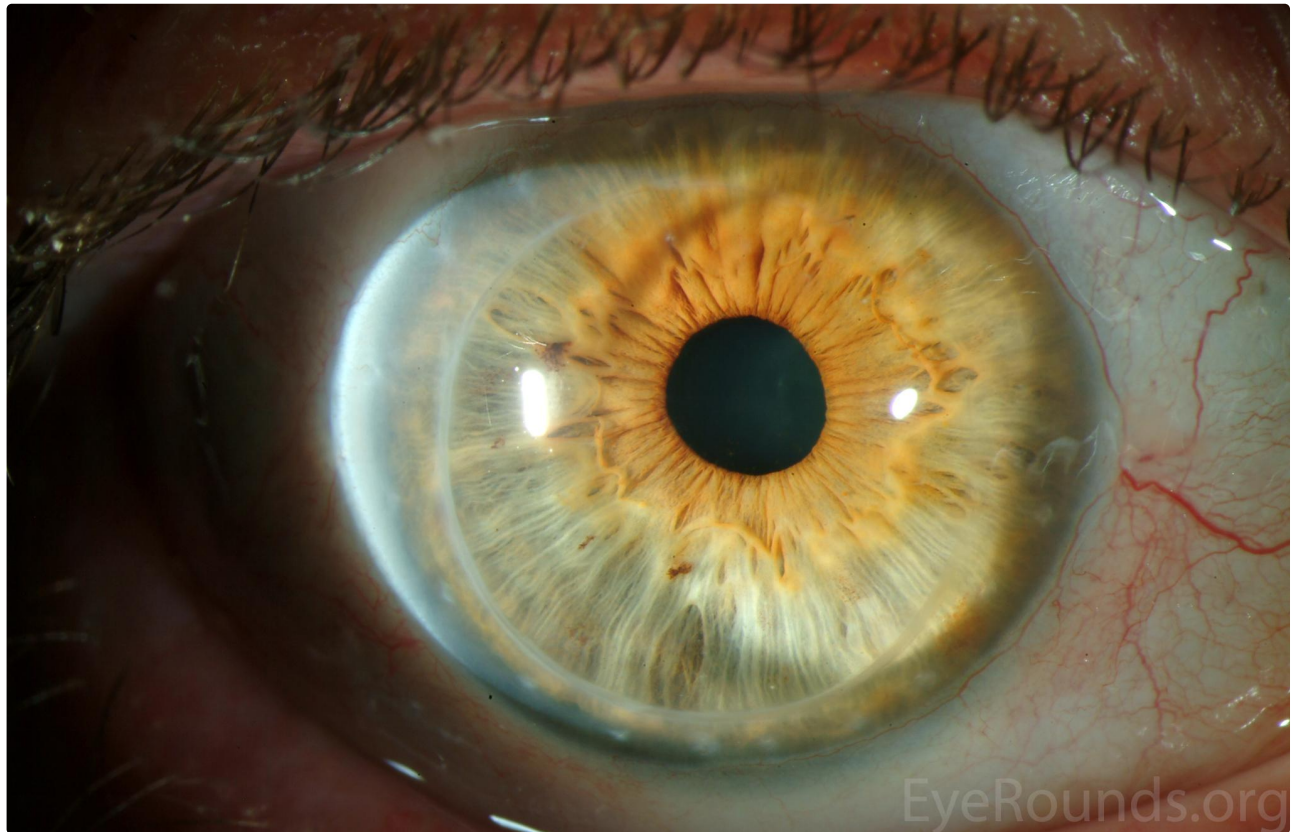




Combination of Running Sutures and Interrupted Sutures

[Enlarge](#)

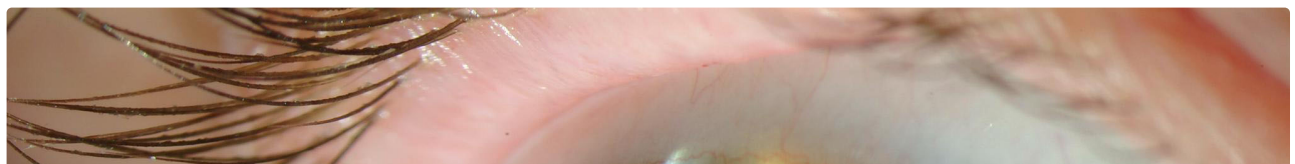[Download](#)

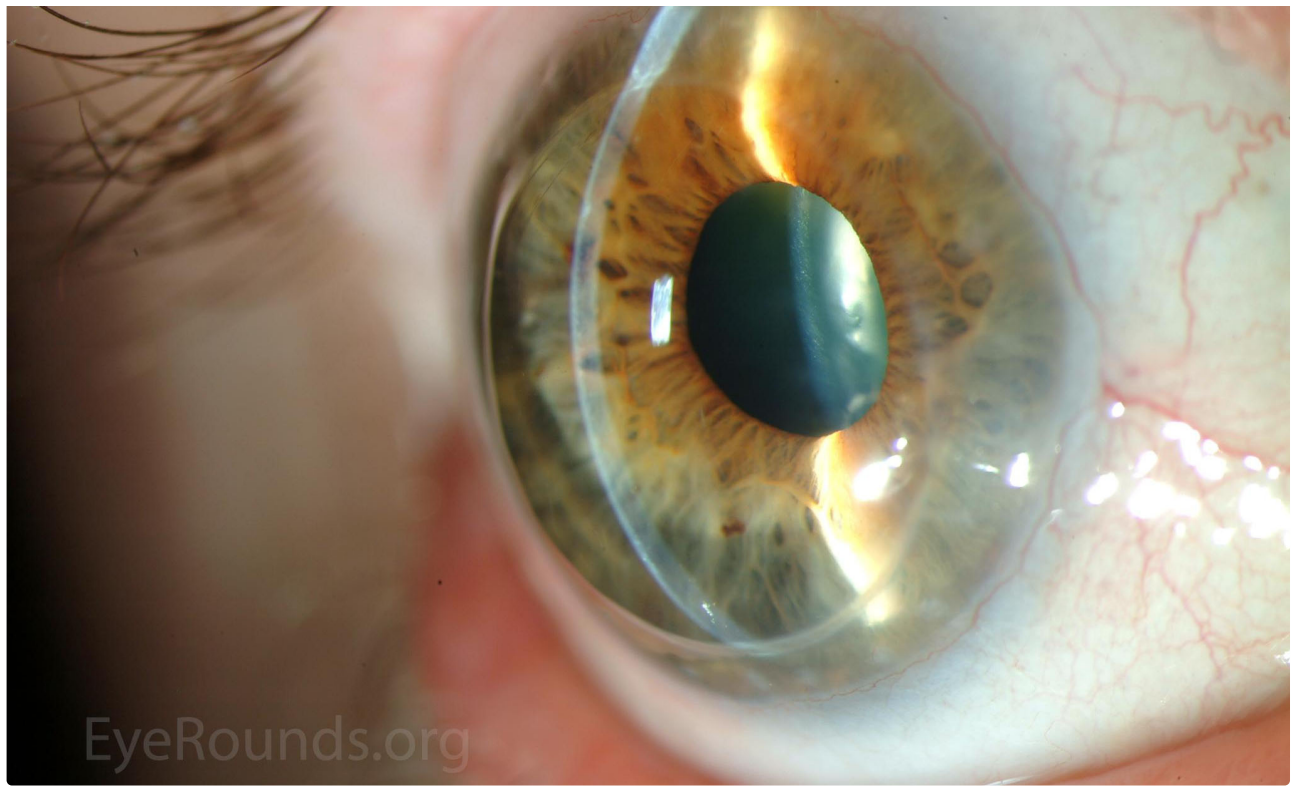


Grafts may remain clear for decades with proper care, as seen in this patient 30 years after the procedure with all sutures removed

[Enlarge](#)

[Download](#)





Grafts may remain clear for decades with proper care, as seen in this patient 30 years after the procedure with all sutures removed

[Enlarge](#)

[Download](#)

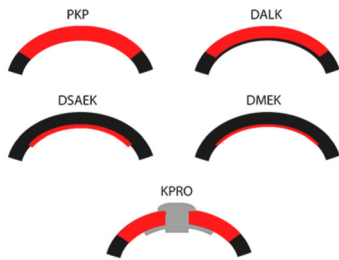Image Permissions:



Ophthalmic Atlas Images by [EyeRounds.org](#), [The University of Iowa](#) are licensed under a [Creative Commons Attribution-NonCommercial-NoDerivs 3.0 Unported License](#).



Related Articles



[Related Tutorial: An Introduction to Corneal Transplantation](#)

Address

University of Iowa
Roy J. and Lucille A. Carver College
of Medicine
Department of Ophthalmology and
Visual Sciences
200 Hawkins Drive
Iowa City, IA 52242

[Support Us](#)

Legal

Copyright © 2019 The University of
Iowa. All Rights Reserved
[Report an issue with this page](#)
[Web Privacy Policy](#) |
[Nondiscrimination Statement](#)

Related Links

[Cataract Surgery for Greenhorns](#)
[EyeTransillumination](#)
[Gonioscopy.org](#)
[Iowa Glaucoma Curriculum](#)
[Iowa Wet Lab](#)
[Patient Information](#)
[Stone Rounds](#)
[The Best Hits Bookshelf](#)

EyeRounds Social Media

Follow



[Receive notification of new cases,
sign up here](#)
[Contact Us](#)
[Submit a Suggestion](#)